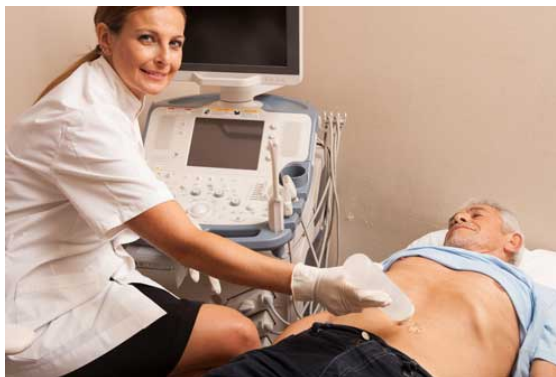


Fatty Liver Disease and Liver Fibrosis

Fatty Liver Disease (FLD) is a condition where normal liver tissue is replaced by more than 5-6 percent fat. In FLD, the accumulation of fat can cause inflammation, cell death, and scarring – a condition called steatohepatitis. Left untreated, steatohepatitis can lead to liver fibrosis which causes diminished blood flow throughout the liver and a buildup of scar tissue. Without treatment, liver fibrosis may lead to cirrhosis, liver failure, and liver cancer.

Your doctor will conduct a physical exam and may order blood tests to evaluate your liver function. You also may undergo abdominal ultrasound, abdominal CT, body MRI, ultrasound elastography, magnetic resonance elastography, or liver biopsy to help diagnosis your condition. Treatment for FLD and/or liver fibrosis depends on the underlying cause and is typically aimed at preventing, slowing or reversing the progression of liver fibrosis. Options include lifestyle changes, medication, and cholesterol and diabetes management.



What are Fatty Liver Disease and Liver Fibrosis?

One of the many causes of liver disease is the buildup of too much fat in the organ, called steatosis. The liver normally contains some fat, but more than 5-6 percent of fat is abnormal. The class of liver disease in which liver becomes fatty (or steatotic) is called Fatty Liver Disease (FLD).

There are two major causes of FLD:

- alcoholic fatty liver disease (AFLD), which occurs as a result of drinking excessive quantities of alcohol.
- nonalcoholic fatty liver disease (NAFLD), which occurs as a result of abnormal metabolism. It is associated with obesity, high cholesterol and diabetes. NAFLD is the most common liver disease in developed countries, including the United States.

Other causes of FLD include: viral hepatitis, certain medications including steroids and chemotherapy, and pregnancy.

FLD can progress to a condition called steatohepatitis when the accumulation of fat in the liver causes inflammation, cell death, and scarring. Long-standing steatohepatitis leads to liver fibrosis as scar tissue builds up and replaces healthy liver tissue.

Liver fibrosis results in diminished blood flow throughout the liver. As healthy liver tissue is lost, the liver also loses its ability to function. If untreated, liver fibrosis may progress to cirrhosis of the liver (<https://www.radiologyinfo.org/en/info/cirrhosisliver>), liver failure, and liver cancer.

Unfortunately, many patients with FLD and liver fibrosis do not realize they have liver disease because the symptoms are often vague, like mild fatigue or abdominal discomfort.

As liver disease progresses over time, patients may begin to experience:

- appetite and weight loss
- weakness
- nausea

- yellowing of skin and eyes (jaundice)
- fluid buildup and swelling in legs and abdomen
- confusion and trouble concentrating

How are Fatty Liver Disease and Liver Fibrosis diagnosed and evaluated?

Your doctor will begin by asking you about your medical history and symptoms. You will also undergo a physical exam.

In order to diagnose FLD and liver fibrosis, your doctor may order blood tests to evaluate liver function, including tests to assess the level of the liver enzymes ALT and AST, which can be high when the liver is fatty.

Your doctor may also order imaging tests of the liver such as:

- Abdominal Ultrasound (<https://www.radiologyinfo.org/en/info/abdominus>), which uses sound waves to produce pictures to evaluate the size and shape of the liver, as well as blood flow through the liver. On ultrasound images, steatotic livers look brighter than normal livers, and cirrhotic livers (advanced fibrosis) look lumpy and shrunken.
- Computed Tomography (CT) of the abdomen and pelvis (<https://www.radiologyinfo.org/en/info/abdominct>) that combines special x-ray equipment with sophisticated computers to produce multiple images or pictures of the inside of the body. On CT, steatotic livers look darker than normal livers. Cirrhotic livers look lumpy and shrunken.
- Magnetic resonance imaging (MRI) (<https://www.radiologyinfo.org/en/info/bodymr>) uses a magnetic field and radio waves to produce detailed pictures of the liver. MRI is the most sensitive imaging test for steatosis, highly accurate even in mild steatosis. When a special technique is used, MRI can calculate the percentage of fat in the liver. More than 5-6% of fat in the liver is considered abnormal.
- Ultrasound elastography is a special ultrasound technique to test for liver fibrosis. The movement of the liver caused by ultrasound wave is measured in the middle of the liver, and its stiffness (or elasticity) is calculated. Fibrotic livers are stiffer and moves to a greater degree compared to normal livers.
- MR elastography (MRE) is a special MRI technique to test for liver fibrosis. The movement of fine vibration waves in the liver is imaged to create a visual map, or elastogram, that shows the stiffness (or elasticity) across the liver. Both ultrasound and MR elastography can detect increased stiffness of the liver caused by liver fibrosis earlier than other imaging tests and may eliminate the need for an invasive liver biopsy.
- Liver biopsy (<https://www.radiologyinfo.org/en/info/biopgen>) is an image-guided procedure that removes a small sample of liver tissue using a needle. The sample is then examined under a microscope for signs of steatosis, inflammation and damage, and fibrosis.

How are Fatty Liver Disease and Liver Fibrosis treated?

Treatment for FLD and liver fibrosis varies depending on the cause. Doctors typically recommend treatment aimed at preventing or delaying progression of fibrosis. With treatment, the progression of liver disease can be slowed and may be reversed.

For example, therapies for NAFLD may include:

- dietary changes
- anti-inflammatory medications and medications for insulin resistance
- cholesterol and diabetes management
- exercise and weight loss
- eliminating alcohol use

Which test, procedure, or treatment is best for me?

- *Abnormal Liver Function Tests* (<https://www.radiologyinfo.org/en/info/acs-abnorm-liver-tests>)
- *Chronic Liver Disease* (<https://www.radiologyinfo.org/en/info/acs-chronic-liver-disease>)
- *Jaundice* (<https://www.radiologyinfo.org/en/info/acs-jaundice>)

Disclaimer

This information is copied from the RadiologyInfo Web site (<http://www.radiologyinfo.org>) which is dedicated to providing the highest quality information. To ensure that, each section is reviewed by a physician with expertise in the area presented. All information contained in the Web site is further reviewed by an ACR (American College of Radiology) - RSNA (Radiological Society of North America) committee, comprising physicians with expertise in several radiologic areas.

However, it is not possible to assure that this Web site contains complete, up-to-date information on any particular subject. Therefore, ACR and RSNA make no representations or warranties about the suitability of this information for use for any particular purpose. All information is provided "as is" without express or implied warranty.

Please visit the RadiologyInfo Web site at <http://www.radiologyinfo.org> to view or download the latest information.

Note: Images may be shown for illustrative purposes. Do not attempt to draw conclusions or make diagnoses by comparing these images to other medical images, particularly your own. Only qualified physicians should interpret images; the radiologist is the physician expert trained in medical imaging.

Copyright

This material is copyrighted by either the Radiological Society of North America (RSNA), 820 Jorie Boulevard, Oak Brook, IL 60523-2251 or the American College of Radiology (ACR), 1891 Preston White Drive, Reston, VA 20191-4397. Commercial reproduction or multiple distribution by any traditional or electronically based reproduction/publication method is prohibited.

Copyright © 2024 Radiological Society of North America, Inc.