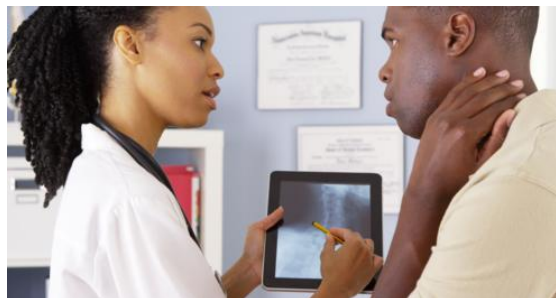


## Osteonecrosis

Osteonecrosis, also called avascular necrosis, is a condition where a lack of blood supply causes damage to the bone. When osteonecrosis occurs, the bone loses its blood supply and its ability to heal from damage. It is most common in bones near joints such as the ankle, wrist, hip, and shoulder. In the later stages of the disease, the affected bone can break and collapse.

Your doctor will perform a physical exam and ask questions about conditions that may affect your bones and the medicines and supplements you take. Imaging tests, including X-rays and MRI, may be used to look for signs of the disease. Non-surgical treatments such as pain medication and physical therapy may slow the progression of the disease and relieve pain. However, some patients may require surgery.



### What is osteonecrosis?

Osteonecrosis, also called avascular necrosis, is a condition where a lack of blood supply causes damage to the bone. Healthy bone is always changing. Portions of bone that break down due to our normal exercise and daily activity continually heal. In osteonecrosis, the bone loses its blood supply and its ability to heal. It is most common in bones near joints such as the ankle, wrist, hip, and shoulder. As the disease progresses, the bone may crack and collapse. If this occurs to a bone inside a joint, it can cause pain and difficulty moving your joint. It may also damage nearby bones and your surrounding cartilage.

Osteonecrosis may occur after severe trauma, such as a bone fracture or dislocation. In some cases, there is no known cause of the disease. In other patients, a combination of factors may result in osteonecrosis. Other causes and risk factors for the disease include:

- prolonged use of oral or intravenous steroids
- heavy alcohol use
- smoking
- blood clotting disorders
- HIV infection or taking HIV drugs
- radiation therapy or chemotherapy
- decompression sickness from deep sea diving
- sickle cell disease
- Gaucher disease (a buildup of certain fatty substances in certain organs, particularly the spleen and liver, that can affect their function)
- systemic lupus erythematosus (an autoimmune disease in which the immune system attacks its own tissues)
- Legg-Calve-Perthes (a rare childhood condition that affects the hip)
- diabetes
- receiving an organ transplant
- pancreatitis
- autoimmune disease

- cancer

Patients with osteonecrosis may not have symptoms at first. As the amount of bone involved increases or if part of the bone breaks patients experience pain, especially when using the affected joint. The affected joint may develop osteoarthritis (<http://www.radiologyinfo.org>) .

Other symptoms include joint stiffness and limited range of motion. The disease usually occurs between the ages of 20 and 50.

## How is osteonecrosis diagnosed and evaluated?

Early diagnosis and intervention are essential to stop further damage to the affected bone and joint. Your doctor will perform a physical exam and ask questions about conditions that may affect your bones and the medicines and supplements you take. The doctor may use X-ray or MRI to confirm a diagnosis.

**Bone X-ray:** This exam produces pictures of the bone with a very small dose of radiation. *See the Bone X-ray* (<https://www.radiologyinfo.org/en/info/bonerad>) page for more information.

**MRI (magnetic resonance imaging):** This imaging test uses a magnetic field and radio frequency pulses to produce detailed pictures of the internal organs. It does not involve radiation. MRI can detect osteonecrosis in its earliest stages. *See the Body MRI* (<https://www.radiologyinfo.org/en/info/bodymr>) page for more information.

## How is osteonecrosis treated?

In the early stages of the disease, your treatment may include:

- cold packs
- heat treatment
- rest
- non-steroidal anti-inflammatory drugs (NSAIDs)
- physical therapy to ease joint tenderness and increase range of motion
- walking aids such as canes and crutches

These non-surgical treatments can often slow the progression of the disease. Some patients with osteonecrosis may need additional more invasive treatment such as:

### **Bone decompression**

In this surgical procedure, a physician drills a tunnel into the affected bone. This procedure works best before the collapse of a diseased bone. This treatment aims to restore blood flow to the area, reduce pain, and slow the progression of bone destruction.

### **Bone graft**

After a core decompression, the doctor inserts healthy bone into the drilled holes to strengthen the diseased area. The patient or a donor may provide the bone; synthetic bone tissue is also an option. In some cases, the physician will use bone tissue and its blood supply (vascularized) to help strengthen the bone and restore blood flow to the area.

### **Osteotomy**

In this surgical procedure, a physician reshapes the diseased bone and changes its alignment to reduce stress on the area.

### **Total joint replacement (arthroplasty)**

This surgical procedure aims to replace the affected joint with an artificial metal, ceramic or plastic joint.

## Disclaimer

This information is copied from the RadiologyInfo Web site (<http://www.radiologyinfo.org>) which is dedicated to providing the highest quality information. To ensure that, each section is reviewed by a physician with expertise in the area presented. All information contained in the Web site is further reviewed by an ACR (American College of Radiology) - RSNA (Radiological Society of North America) committee, comprising physicians with expertise in several radiologic areas.

However, it is not possible to assure that this Web site contains complete, up-to-date information on any particular subject. Therefore, ACR and RSNA make no representations or warranties about the suitability of this information for use for any particular purpose. All information is provided "as is" without express or implied warranty.

Please visit the RadiologyInfo Web site at <http://www.radiologyinfo.org> to view or download the latest information.

**Note:** Images may be shown for illustrative purposes. Do not attempt to draw conclusions or make diagnoses by comparing these images to other medical images, particularly your own. Only qualified physicians should interpret images; the radiologist is the physician expert trained in medical imaging.

## Copyright

This material is copyrighted by either the Radiological Society of North America (RSNA), 820 Jorie Boulevard, Oak Brook, IL 60523-2251 or the American College of Radiology (ACR), 1891 Preston White Drive, Reston, VA 20191-4397. Commercial reproduction or multiple distribution by any traditional or electronically based reproduction/publication method is prohibited.

Copyright © 2025 Radiological Society of North America, Inc.